

PATIENT

Rosie Smith

SPECIES

Canine

BREED

Beagle

SEX

Female Spayed

AGE

6 years

WEIGHT

25lbs

INTERPRETED BY

Maggie Machen Lamy,
DVM, DACVIM
(Cardiology)

IMAGING PERFORMED BY

Karen Ebersole,
DVM, DABVP

HOSPITAL NAME

Scanvet

REFERRING VET

Dr. Bailey

INVOICE

28800

DATE

2/6/23

PRESENTING CLINICAL SIGNS

History: Grade 5/6 systolic heart murmur w/palpable thrill. Assess prior to anesthesia.

ECHOCARDIOGRAM FINDINGS

2D, m-mode, color flow and doppler imaging is available. Diffuse thickening of mitral valve leaflets (anterior>posterior) with mild prolapse into the left atrial lumen. Moderate to severe eccentric mitral regurgitation with moderate left atrial dilation. Normal MR velocity. Mildly increased LV diameter with adequate myocardial function. The tricuspid valve appears mildly thickened with mild tricuspid regurgitation. Normal right atrial and ventricular diameter. The pulmonic and aortic valves are normal in morphology and mobility. Normal pulmonic and aortic outflow velocities. No aortic and trace pulmonic insufficiency. No pericardial or pleural effusion noted. No cardiac tumors observed.

CARDIAC CHART

CANINE CARDIAC PARAMETERS	MR VMAX (m/s)	TR VMAX (m/s)	LA/AO (Boon method)	LA/AO (Heart Base; Swe)	FS (%)	EF (%)	EPSS (cm)
NORMAL PARAMETER	4.5-5.5	<2.7	1.3	<1.6	28-40	40-100	<0.6
PATIENT	5.5	NM	NM	1.7	45	77	0.3
CANINE CARDIAC PARAMETERS	HR (BPM)	AV VMAX (m/s)	PV MAX (m/s)	BODY WEIGHT (kg)	LA 2D short axis Base view (cm)	LVIDd Avg; 2D and m-mode short axis (cm)	LVIDs Avg; 2D and m-mode short axis (cm)
NORMAL PARAMETER	50-100	0.7-1.7	0.7-1.6	BELOW	BELOW	BELOW	BELOW
PATIENT	86	1.9	1.2	11.3	3.2	3.9	2.2
*Normal chamber parameters expressed as a mean value (SD)				3	1.27 (5.3)	2.46 (2.46)	1.36 (5.5)
BODY WEIGHT DEPENDENT PARAMETERS				5	1.40 (4.5)	2.74 (5.2)	1.60 (4.7)
<i>*Note: All measurements based upon multi-modal images and methods. An average value is reported.</i>				10	1.50 (3.8)	3.27 (3.5)	2.06 (3.1)
				15	1.83 (2.0)	3.71 (2.4)	2.43 (2.1)
				20	2.02 (1.9)	4.14 (2.2)	2.80 (2.0)
				25	2.18 (2.4)	4.48 (2.9)	3.10 (2.5)
				30	2.33 (3.3)	4.83 (3.9)	3.39 (3.4)
				35	2.48 (4.3)	5.17 (5.0)	3.69 (4.5)
				40	2.62 (5.2)	5.48 (6.1)	3.96 (5.4)
				50	2.88 (7.1)	6.07 (8.3)	4.46 (7.4)

INTERPRETATION OF THE FINDINGS & FURTHER RECOMMENDATIONS

Chronic degenerative valve disease causing moderate to severe mitral and mild tricuspid regurgitation. Moderate left atrial enlargement indicates there is relatively low risk for imminent complication, however risk for progression to spontaneous congestive heart failure in the future is elevated. No additional issues are identified.

Given the risk for progression and results of the EPIC trial, Pimobendan is indicated in this patient as below. Additionally an ACEI is reasonable pending BP assessment. Assessment of progression in the future will help predict long term outcome, however prognosis is guarded at this stage (B2).



PATIENT

Rosie Smith

Omega fatty acid supplementation and mild salt restriction may also be of some long-term benefit. Monitor for development of a progressive cough, labored breathing, exercise intolerance or collapse episodes.

SPECIES

Canine

Once on the medication for 3-5 days, anesthetic risk is considered moderately elevated. Cardiac protective drug choices (opioid/benzodiazepine premedication, Propofol or alfaxalone induction, iso or sevo gas) are recommended. Monitor for arrhythmias, hypotension, and hypoxia both intra and post-operatively and intervene as necessary. Judicious IV fluid rates are recommended to avoid fluid overload. Avoid heart rate stimulating drugs such as atropine unless clinically indicated.

BREED

Beagle

SEX

Female Spayed

PLAN

Institute heart muscle support Pimobendan 0.25-0.3mg/kg PO q12h. Baseline BP recommended. If >130mmHg, institute ACEI 0.5mg/kg PO q12h.

AGE

6 years

Recommend monitor for progression with a recheck echocardiogram in 6 months, sooner if any development of clinical signs.

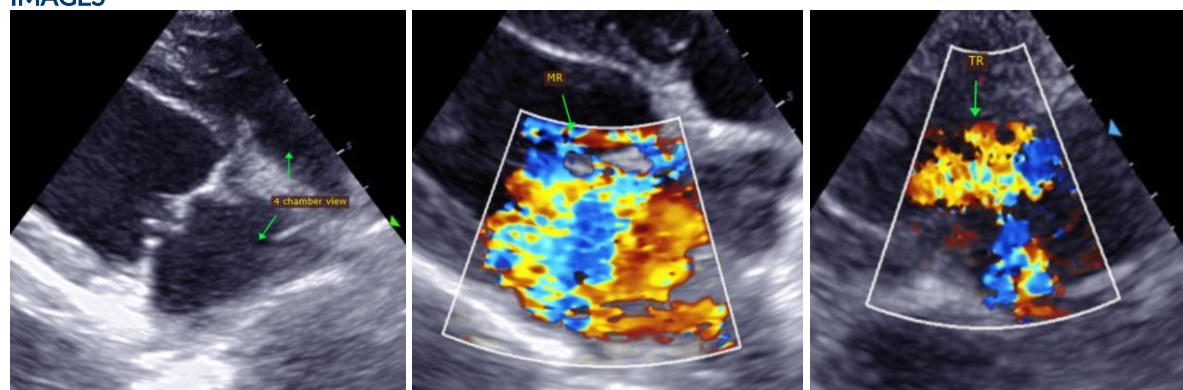
WEIGHT

25lbs

IMAGES

INTERPRETED BY

Maggie Machen Lamy, DVM, DACVIM (Cardiology)



IMAGING PERFORMED BY

Karen Ebersole, DVM, DABVP

The information and recommendations provided are based on the images presented by the referring veterinarian. No evaluation can be communicated regarding pathology that was not visible in the image/video clips provided.

HOSPITAL NAME

Scanvet

Thank you for this referral. This report was generated using transcription software, and minor dictation errors may be present. If the clinical or image interpretation does not parallel your findings or if I can be of any further assistance, please contact me.

REFERRING VET

Dr. Bailey

Maggie Machen Lamy, DVM
Diplomate of the American College of Veterinary Internal Medicine (Cardiology)
info@sonopath.com

INVOICE

28800

DATE

2/6/23



PATIENT

Rosie Smith

SPECIES

Canine

BREED

Beagle

SEX

Female Spayed

AGE

6 years

WEIGHT

25lbs

INTERPRETED BY

Maggie Machen Lamy,
DVM, DACVIM
(Cardiology)

**IMAGING
PERFORMED BY**

Karen Ebersole,
DVM, DABVP

HOSPITAL NAME

Scanvet

REFERRING VET

Dr. Bailey

INVOICE

28800

DATE

2/6/23